

# Peripheral Neuropathies Associated With Monoclonal Gammopathies

DR SAJAD AHMAD TAK ( DNB SCHOLAR)

# Introduction


- ▶ Monoclonal gammopathy occurs in about 3.2% of individuals older than 50 year.
- ▶ more than 5% of individuals older than 70 years of age
- ▶ Affect men more than women, with increasing incidence with age.

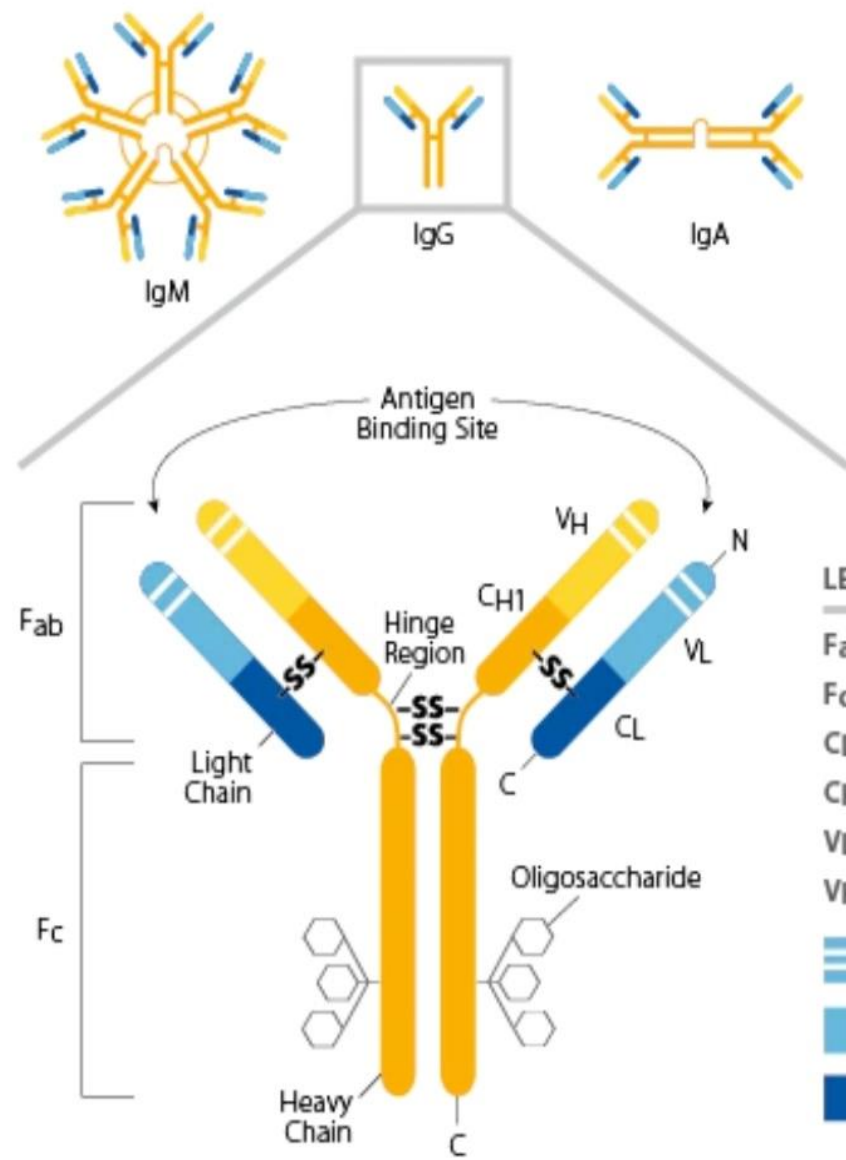
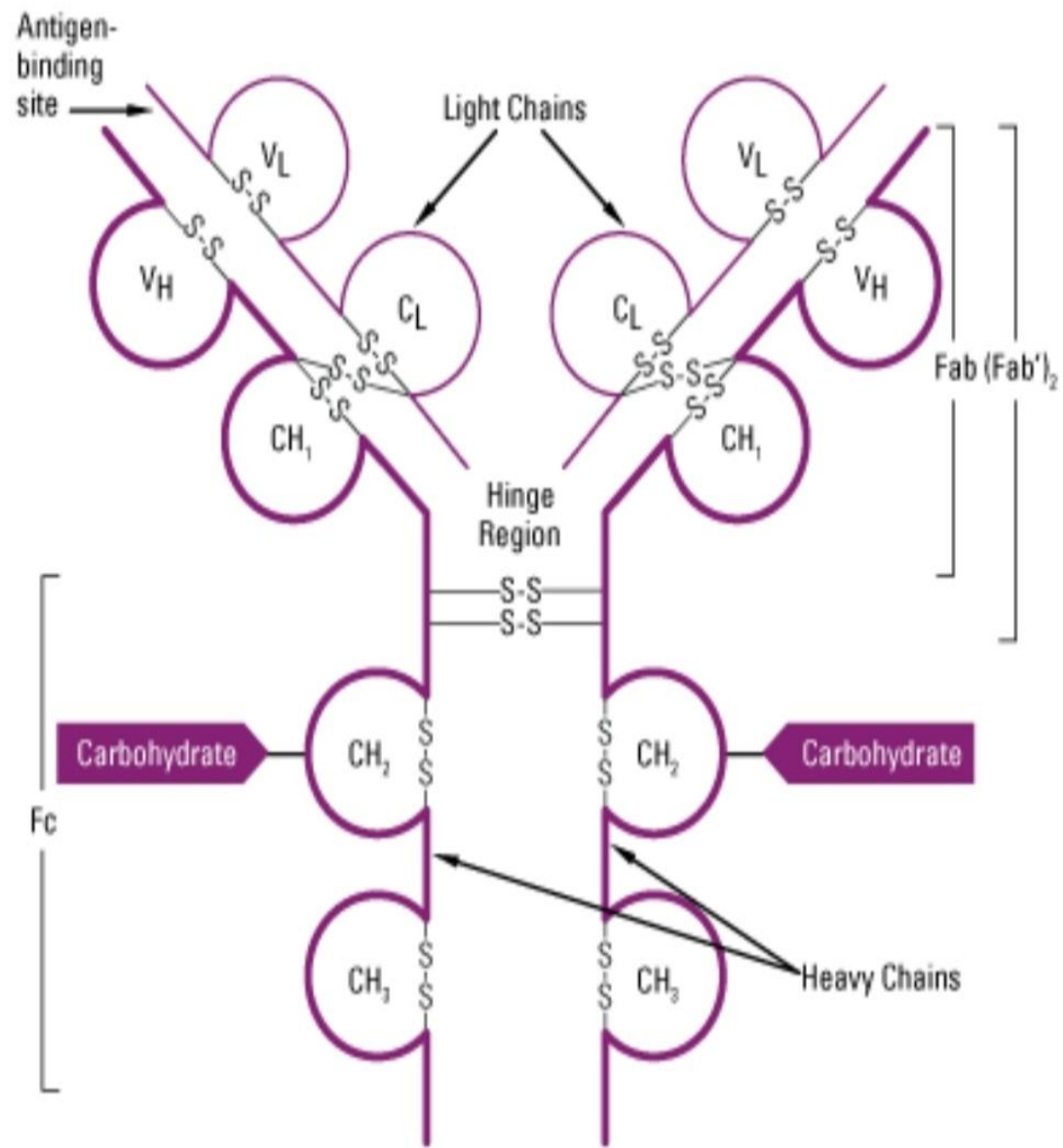


**Nerve involvement** occurs because of;

- ▶ Abnormal cell proliferation in which a monoclonal gammopathy is the sign of an underlying lymphoproliferative disorder directly involving nerves;
- ▶ high protein burden and protein deposition as seen in amyloidosis; or
- ▶ immune-mediated via autoantibody activity, activation of complement pathway, or secretion of cytokines

# MONOCLONAL GAMMOPATHY

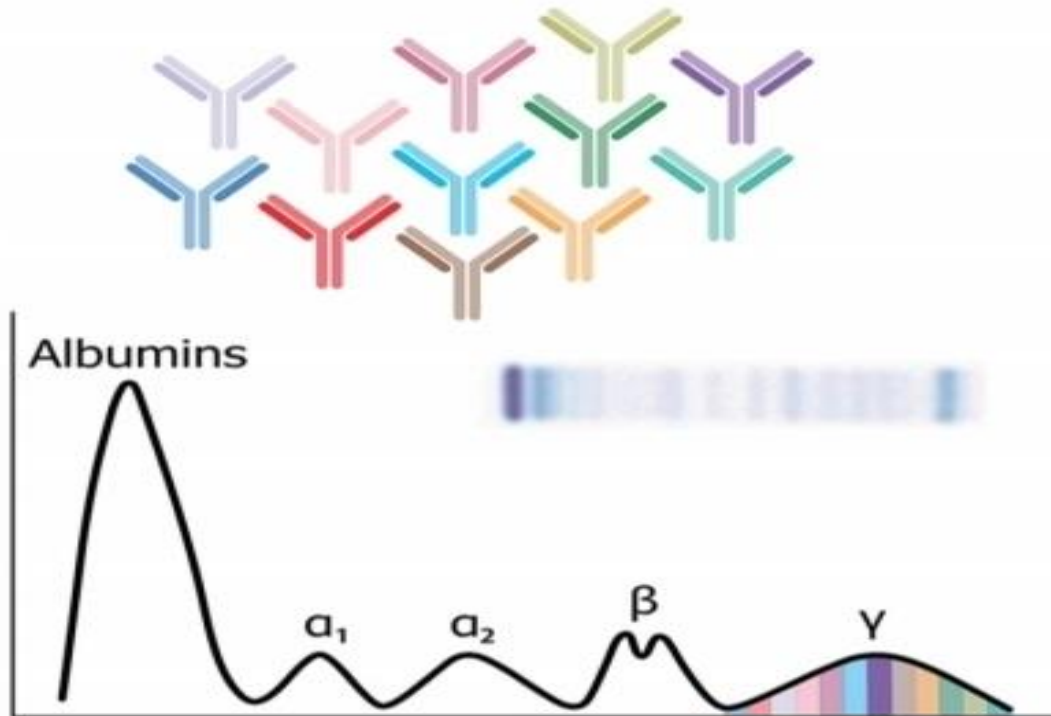
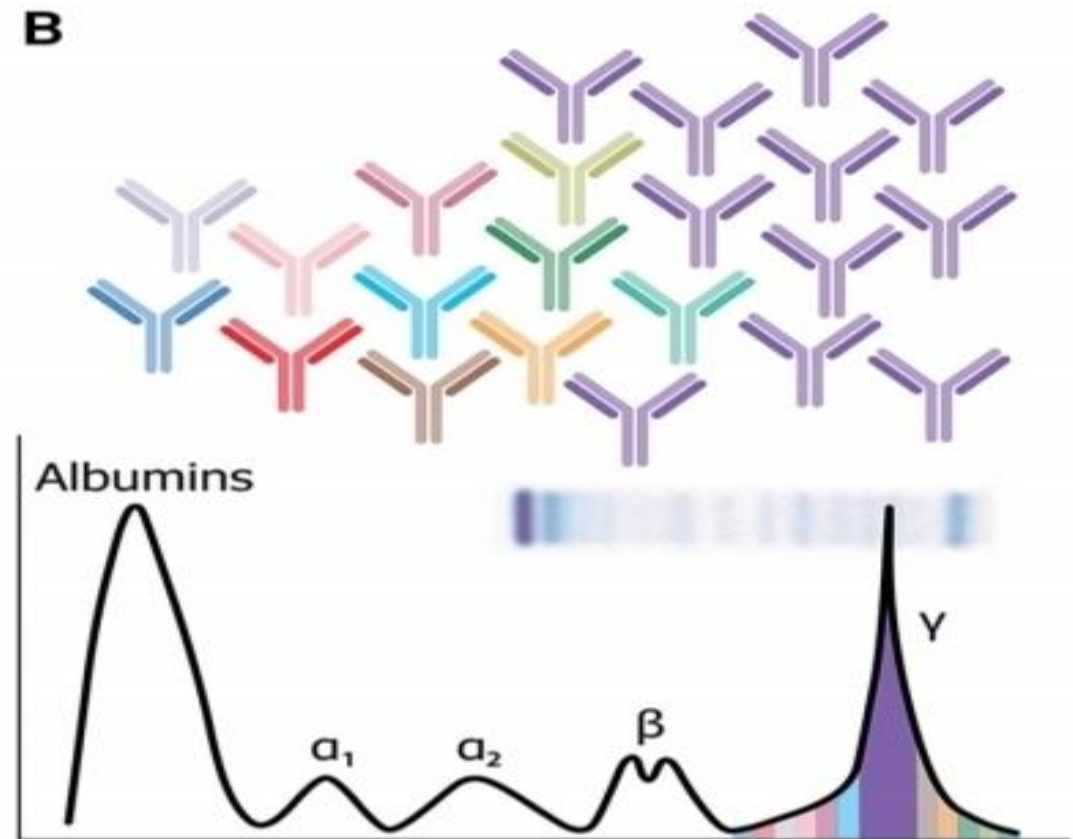





- LEGEND**
- Fab Fragment, antigen-binding
  - Fc Fragment, crystallizable
  - CL Constant domain, Light Chain
  - CH Constant domain, Heavy Chain
  - VL Variable domain, Light Chain
  - VH Variable domain, Heavy Chain
  - ▬▬▬ Hypervariable Region
  - ▬▬▬ Variable Region
  - ▬▬▬ Constant Region

Generalized structure of an immunoglobulin (IgG).

Annotated diagram of immunoglobulin structure.

**A****B****FIGURE 11-1**


**Monoclonal gammopathy representation. A, In normal state, antibodies of different colors result in a wide-based curve on serum protein electrophoresis. B, Proliferation of a purple clone results in a spike on top of the wide-based curve on serum protein electrophoresis, representing the monoclonal spike.**


- 
- ▶ We will mainly encounter monoclonal gammopathies of the IgG, IgA, or IgM heavy chain subtypes and either kappa or lambda light chain subtypes.
  - ▶ It is also possible for the monoclonal gammopathy to be light chain only.
  - ▶ According to the International Myeloma Working Group, serum protein electrophoresis, serum immunofixation, and quantification of free light chains in the serum should be sufficient to screen for a monoclonal gammopathy, with a sensitivity of more than 97%.

# Significance of a Monoclonal Gammopathy

- ▶ As a monoclonal gammopathy indicates the presence of an underlying clonal plasma cell disorder,
- ▶ the significance from a hematologic perspective varies, ranging from benign to a malignant lymphoplasma-cytic disorder.
- ▶ Monoclonal gammopathy of undetermined significance (MGUS).....a low serum monoclonal protein level (<3 g/dL),  
less than 10% plasma cells in the bone marrow, and  
less than 500 mg/24 hour of M protein in the urine) and  
no evidence of end organ damage.



- 
- ▶ MGUS carries an inherent lifelong risk of progression into a lymphoplasmacytic malignancy of about 1% per year.
  - ▶ Whereas a monoclonal gammopathy may be of undetermined significance from a hematologic standpoint,
  - ▶ it may still be of clinical significance from a neurologic standpoint.

- 
- ▶ **Monitoring of Monoclonal Gammopathy of Undetermined Significance;**
  - ▶ **High-risk factors for progression into a lymphoplasmacytic malignancy are IgM subtype,**

**M-spike** greater than or equal to 1.5 g/dL, and

Abnormal serum **free light chain ratio**. ( with normal kappa to lambda ratio ..... normal range 0.26 to 1.65).



▶ Further investigation to rule out an underlying malignancy,

including a bone marrow biopsy in patients with all subtypes and

the addition of a skeletal survey in patients with IgG and IgA subtypes.


All patients with MGUS should have a repeat evaluation with complete blood cell count, serum protein electrophoresis, free light chains, and calcium and creatinine levels in 6 months and on a yearly basis thereafter.


# IgM-Associated Disorders

- ▶ IgM is the most common monoclonal gammopathy subtype encountered in patients with peripheral neuropathy.
- ▶ **IgM MONOCLONAL GAMMOPATHY OF UNDETERMINED SIGNIFICANCE**;.... IgM peripheral neuropathy usually presents with

progressive sensory loss resulting in gait ataxia,


with no to minimal weakness (distal acquired demyelinating symmetric [DADS] phenotype)

- 
- ▶ IgM peripheral neuropathy, distal acquired demyelinating symmetric (DADS) phenotype, is a demyelinating neuropathy with characteristic prolongation of motor distal latencies on electrodiagnostic testing.
  - ▶ Sensory responses are often absent.
  - ▶ Approximately 50% of patients have antibodies to myelin-associated glycoprotein (MAG); hence, the neuropathy is sometimes called anti-MAG neuropathy


- 
- ▶ When patients present with sensory symptoms predominantly affecting small fiber modalities without significant large fiber involvement and lack of demyelinating features on nerve conduction studies, it is more likely that the presence of IgM MGUS is coincidental.
  - ▶ Only anecdotal evidence exists to support the use of immunotherapy in IgM neuropathy, as most clinical trials showed no benefit or only marginal benefit.<sup>13</sup> Rituximab can be considered on a case-by-case basis

# WALDENSTRÖM MACROGLOBULINEMIA.

- ▶ By definition an IgM lymphoplasmacytic lymphoma,
- ▶ Similar clinical presentation to IgM neuropathy, with progressive length-dependent sensory loss, gait ataxia, and minimal weakness.
- ▶ Occasionally, Waldenström macroglobulinemia–associated peripheral neuropathy may present as a polyradiculoneuropathy mimicking CIDP.

- 
- ▶ systemic symptoms of weight loss, night sweats, and fatigue.
  - ▶ Patients with Waldenström macroglobulinemia can also have hepatosplenomegaly, dysautonomia, and other organ involvement.
  - ▶ Neuropathy can be either axonal or demyelinating.
  - ▶ Demyelination is observed in one-third of patients and, when present, is predominantly distal.



- 
- ▶ unlike in IgM neuropathy, patients with Waldenström macroglobulinemia can have associated anemia, thrombocytopenia, cryoglobulinemia, and significantly greater level of IgM monoclonal gammopathy.
  - ▶ Less commonly, patients with Waldenström macroglobulinemia may also have peripheral nerve involvement from neurolymphomatosis, vasculitis, or cryoglobulinemia.
  - ▶ A non-length-dependent or multifocal pattern and the presence of significant pain should raise concern for an infiltrative or vasculitic process.

# OTHER IgM-ASSOCIATED DISORDERS.


- ▶ **CANOMAD** (chronic ataxic neuropathy, ophthalmoplegia, IgM paraprotein, cold agglutinins, and disialosyl antibodies) is a rare peripheral neuropathy resembling Miller Fisher syndrome but chronic rather than acute.
- ▶ Patients may have ataxia, ophthalmoplegia, bulbar weakness, and facial numbness,
- ▶ IgM antibodies reacting principally with disialosyl epitopes (usually anti-GD1b; sometimes with cross-reactivity against other disialosyl gangliosides, including GQ1b).
- ▶ can be treated with IVIg or rituximab.

# Non-IgM-Associated Disorders


- ▶ IgG and IgA monoclonal gammopathy can be associated with underlying myeloma or amyloidosis.
- ▶ No clear association between IgG and IgA MGUS and peripheral neuropathy has been established.
- ▶ Therefore, in the absence of underlying multiple myeloma, osteosclerotic myeloma, or amyloidosis,  
the presence of an IgG or IgA monoclonal gammopathy in a patient with a peripheral neuropathy is more likely to be coincidental.

# MULTIPLE MYELOMA.

- ▶ plasma cell malignancy of the bone marrow.
- ▶ The cardinal features of multiple myeloma are hypercalcemia, renal failure, anemia, and bone pain.
- ▶ The most frequent neurologic complication is compressive radiculopathy.
- ▶ Chemotherapy-induced peripheral neuropathy is the most frequent cause of neuropathy in multiple myeloma, often due to treatment with bortezomib or thalidomide.

- 
- ▶ Peripheral neuropathy is reported in 5% to 20% of patients with untreated multiple myeloma.
  - ▶ neuropathy in multiple myeloma without amyloid has been described as length-dependent sensorimotor, sensory, or motor predominant.

Patients with secondary amyloidosis may present with carpal tunnel syndrome and may later develop prominent dysesthesia, dissociated sensory loss with predominant loss of pain and thermal discrimination, autonomic dysfunction, or, rarely, painless weakness without autonomic dysfunction.

- 
- ▶ Nerve conduction studies show a predominantly axonal length-dependent sensorimotor peripheral neuropathy.
  - ▶ Treatment of multiple myeloma neuropathy consists mainly of treating the underlying plasma cell disorder, balancing the risk of neurotoxicity associated with these agents.

# POEMS (POLYNEUROPATHY, ORGANOMEGALY, ENDOCRINOPATHY, MONOCLONAL PLASMA CELL DISORDER, AND SKIN CHANGES) SYNDROME.

- ▶ A rare multisystem paraneoplastic syndrome due to an underlying plasma cell neoplasm.
- ▶ The required major criteria include
- ▶ a monoclonal plasma cell proliferative disorder and polyneuropathy. Patients must also meet
- ▶ one other major criterion, which includes elevated vascular endothelial growth factor (VEGF), the presence of Castleman disease (angiofollicular lymph node hyperplasia), or sclerotic bone lesions.



▶ Minor criteria include


organomegaly, endocrinopathy, characteristic skin changes, papilledema, extravascular volume overload, and thrombocytosis.


VEGF is the cytokine that correlates best with disease activity.

It is expressed in many tissues and is known to target endothelial cells;


it induces rapid and reversible increase in vascular permeability and may be important in angiogenesis.



- 
- ▶ The neuropathy in POEMS syndrome often begins distally in the lower limbs with weakness and sensory loss and can progress rapidly to a polyradiculoneuropathy with proximal and distal weakness and areflexia.
  - ▶ The distal weakness is often severe, with bilateral footdrop and distal leg atrophy.
  - ▶ Pain is often present and is a helpful feature to distinguish POEMS from CIDP.

- 
- ▶ Nerve conduction studies often support a primarily demyelinating length-dependent sensorimotor peripheral neuropathy or diffuse polyradiculoneuropathy.
  - ▶ The demyelination is often uniform throughout the nerve; conduction block and temporal dispersion are less common but can occur.
  - ▶ The monoclonal protein in POEMS syndrome is **lambda** light chain–restricted in more than 95% of patients.
  - ▶ An elevated platelet count is present in more than half of patients with POEMS.

- ▶ VEGF levels greater than 200 pg/mL in plasma and greater than 1920 pg/mL in serum are helpful markers for POEMS syndrome,
- ▶ As patients with POEMS commonly have an endocrinopathy (hypogonadism, hyperprolactinemia, hypothyroidism, glucose intolerance, or adrenal insufficiency), screening via a comprehensive laboratory workup is warranted .
- ▶ Osteosclerotic lesions occur in approximately 95% of patients.
- ▶ Whole-body low-dose CT is more sensitive than plain x-ray in detecting small sclerotic lesions and can also show other features of the disease, such as hepatosplenomegaly, adenopathy, or effusions, including ascites.

- 
- ▶ Treatment for POEMS syndrome is directed at the underlying clonal plasma cell disorder and is based on the extent of plasma cell infiltration.





# Light Chain–Associated Disorders

- 
- ▶ A light chain–only monoclonal gammopathy can be associated with immunoglobulin light chain (AL) amyloidosis and light chain multiple myeloma.


- ▶ **IMMUNOGLOBULIN LIGHT CHAIN AMYLOIDOSIS.**

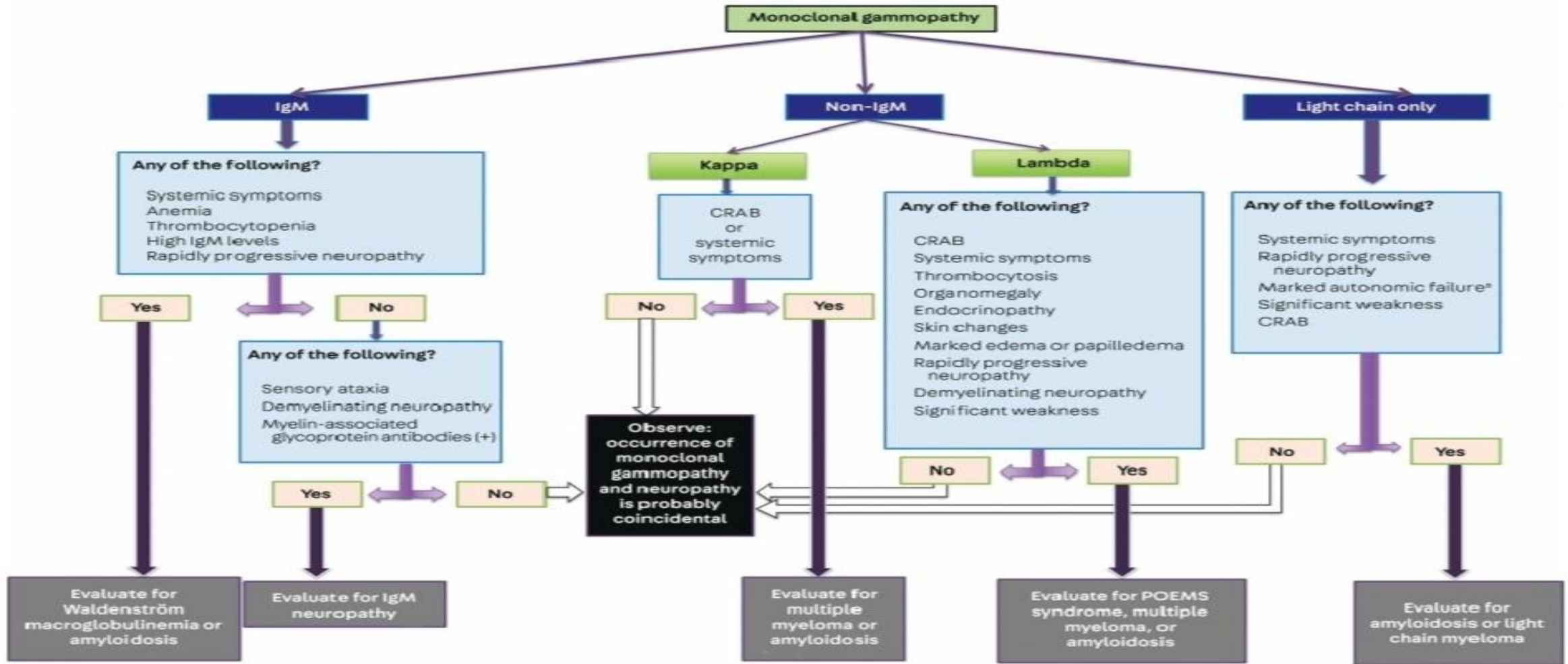
AL amyloidosis is a systemic disorder in which insoluble misfolded light chains deposit into various tissues, including peripheral nerves, which occurs in up to 20% of patients.

- 
- ▶ wide spectrum of symptoms, including cardiorespiratory, gastrointestinal, genitourinary, and systemic symptoms,
  - ▶ Most commonly, patients with AL amyloidosis with peripheral nerve involvement present with generalized autonomic failure and a painful length dependent sensory and motor peripheral neuropathy.
  - ▶ Diagnostic findings of periorbital or facial purpura, hepatomegaly, and macroglossia are seen in a minority of patients. AL amyloid neuropathy should be considered in patients with nephrotic range proteinuria, heart failure with preserved ejection fraction, unexplained hepatomegaly, or diarrhea.

- 
- ▶ On electrodiagnostic testing, amyloid neuropathy is classically a length-dependent sensory and motor predominantly axonal peripheral neuropathy.
  - ▶ In the minority of patients with a pure small fiber sensory neuropathy, electrodiagnostic testing may be normal.
  - ▶ The diagnosis of AL amyloidosis requires demonstration of amyloid deposition in tissue. A surrogate biopsy site, such as abdominal fat pad, bone marrow, minor salivary glands, or skin, is usually attempted first



- 
- ▶ A combined abdominal fat pad and bone marrow biopsy can detect amyloid deposition with a sensitivity of 85%.
  - ▶ If these are negative and the clinical suspicion remains high, then a biopsy from an affected organ or tissue, such as the peripheral nerves, should follow.
  - ▶ The treatment of choice for AL amyloidosis is autologous stem cell transplantation for eligible patients



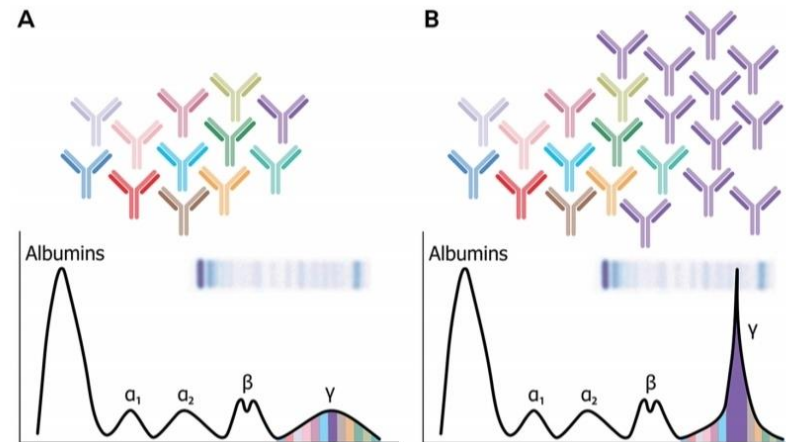
**FIGURE 11-2**

**Algorithmic approach to evaluating patients with a monoclonal gammopathy and peripheral neuropathy.**

CRAB = hypercalcemia, renal failure, anemia, or bone lesions; IgM = immunoglobulin M; POEMS = polyneuropathy, organomegaly, endocrinopathy, monoclonal plasma cell disorder, and skin changes.

<sup>a</sup> The presence of marked autonomic failure with any type of monoclonal gammopathy should raise suspicion for amyloidosis.

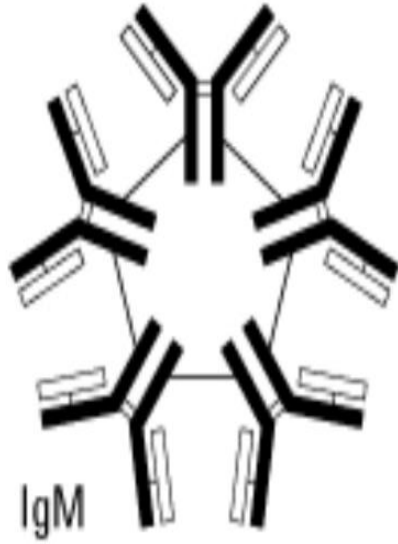
*Thank you*



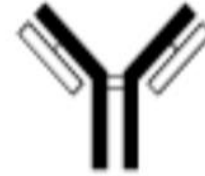**FIGURE 11-1**

Monoclonal gammopathy representation. *A*, In normal state, antibodies of different colors result in a wide-based curve on serum protein electrophoresis. *B*, Proliferation of a purple clone results in a spike on top of the wide-based curve on serum protein electrophoresis, representing the monoclonal spike.

## IgM class



## IgG class



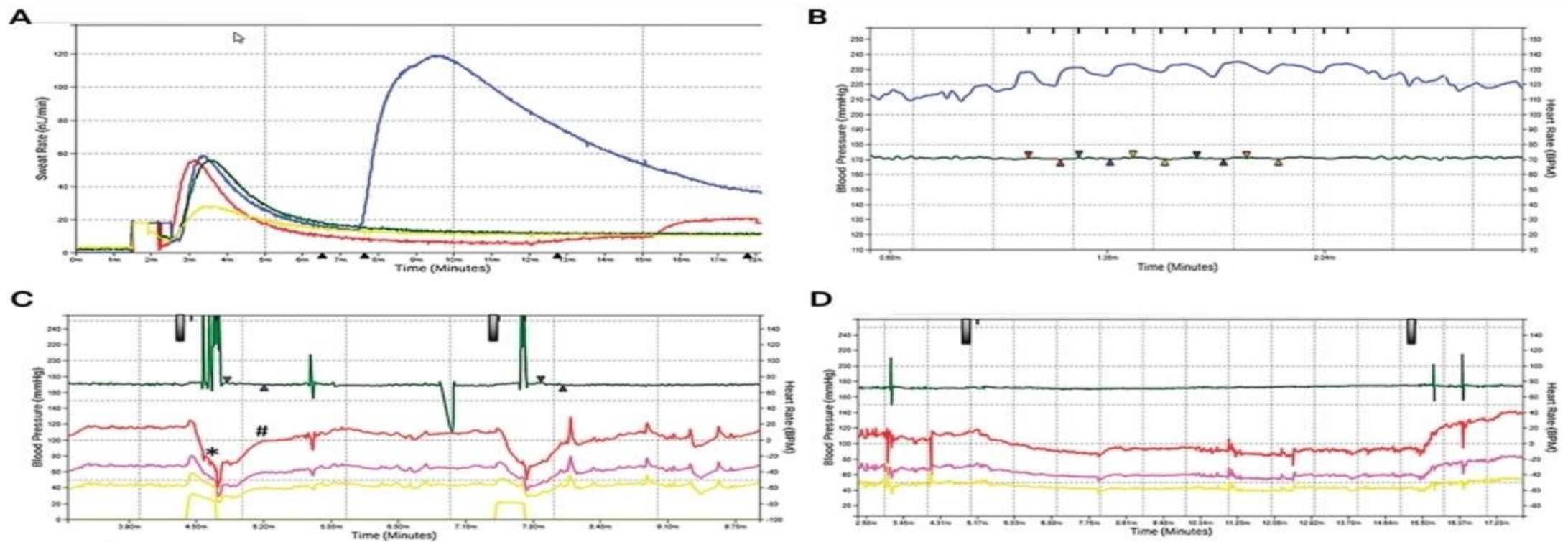
IgG

## Properties of IgM:

- Molecular weight: 900,000
- H-chain type (MW): mu (65,000)
- Serum concentration: 0.5 to 2 mg/mL

## Properties of IgG:

- Molecular weight: 150,000
- H-chain type (MW): gamma (53,000)
- Serum concentration: 10 to 16 mg/mL
- Percent of total immunoglobulin: 75%



**FIGURE 11-4**

Autonomic reflex screen of the patient in **CASE 11-3**. **A**, Quantitative sudomotor axon reflex test (QSART) shows length-dependent postganglionic sympathetic sudomotor dysfunction in sweat output of the forearm (red line), distal leg (green line), and foot (yellow line); sudomotor function in the proximal leg (blue line) is spared. **B**, Heart rate response to deep breathing shows markedly reduced heart rate response (green line with multicolored arrowheads shows maximum and minimum heart rate) to deep breathing (blue line), indicating marked cardiovagal dysfunction. **C**, Valsalva maneuver response shows cardiovagal dysfunction with markedly reduced Valsalva ratio (black bars indicate initiation of Valsalva; green line with arrowheads shows maximum and minimum heart rate) and cardiovascular adrenergic dysfunction as shown by systolic (red line), mean arterial (pink line), and diastolic (yellow line) blood pressure measurements with absent late phase II (asterisk) as well as absent phase IV overshoot and slowed blood pressure recovery time (number sign). **D**, Tilt-table testing (black bars indicate tilt up and tilt down) shows orthostatic hypotension. Red line indicates systolic blood pressure measurement, pink line indicates mean arterial blood pressure measurement, and yellow line indicates diastolic blood pressure measurement. Heart rate response (green line) is also reduced.